

Invisalign Treatment of Dental Class II Malocclusions Without Auxiliaries

KEN FISCHER, DDS

Invisalign* treatment of dental Class II malocclusions in adolescents and young adults is not commonly attempted, even by orthodontists who have significant experience with aligners. Furthermore, the need for auxiliaries such as Class II correctors or elastics makes the technique less appealing to many clinicians. As this article shows, however, there are other successful ways to treat Class II cases using the Invisalign system without auxiliaries.

All three of the patients presented here are adolescent females, each of whom desired treatment without fixed appliances. Since none of the three had a significant skeletal imbalance, an orthopedic corrector such as headgear was not considered necessary for successful treatment.

Case 1

A 13-year-old female presented with the chief complaint of excessive spacing of the anterior teeth (Fig. 1). Her midline was aligned, but she had a dental Class II relationship on the left side. The patient's overbite was slightly excessive. Radiographic evaluation showed a mesognathic, skeletally balanced growth pattern and a straight



Dr. Fischer is in the private practice of orthodontics at 1467 Wanda Road #195, Villa Park, CA 92867; e-mail: df@vorthodontics.com. He is a member of Align Technology's clinical research team and Speakers Bureau.

soft-tissue profile.

The treatment objectives were to close the dental spaces, improve the overbite, and achieve a full Class I occlusion. The ClinCheck* plan involved 35 upper and 35 lower aligners, with an estimated treatment time of 18 months. Class II correction was to be accomplished by advancing the lower posterior segments while simultaneously torquing and retracting the upper anterior teeth (Fig. 2).

Attachments were placed on the upper central incisors through first molars and on the lower left and right premolars, but there was no need for interproximal reduction, midcourse corrections, or refinement aligners. With excellent compliance, the patient completed her active treatment in 16 months. A removable, vacuum-formed upper retainer was delivered, and a passive 3-3 lingual wire was bonded in the lower arch.

With all treatment objectives accomplished, the patient was fully satisfied with her experience (Fig. 3A). Superimposition of the pre- and post-treatment cephalometric tracings showed a small amount of bite opening along with downward and forward mandibular growth (Fig. 3B). The upper and lower molars had developed occlusally and mesially, as would be expected in a patient of this age, and the anterior teeth were retracted and slightly extruded, as the ClinCheck had predicted.

Case 2

This 15-year-old female was bothered by excessive overjet and crowding (Fig. 4). She exhibited a bilateral dental Class II malocclusion with a deep overbite. Radiographs showed a skeletally

*Registered trademark of Align Technology, Inc., 881 Martin Ave., Santa Clara, CA 95050; www.aligntech.com.

balanced, mesognathic craniofacial type and a slightly convex soft-tissue profile.

The objectives in this case were to relieve the crowding, correct the overjet, and treat to a full Class I occlusion. The unconventional ClinCheck plan called for 51 upper and six lower aligners

(Fig. 5). Because the location of the unerupted upper third molars precluded optimal distalization of the first molars, we decided to extract the upper second molars, distalize the first molars into a full

*Registered trademark of Align Technology, Inc., 881 Martin Ave., Santa Clara, CA 95050; www.aligntech.com.

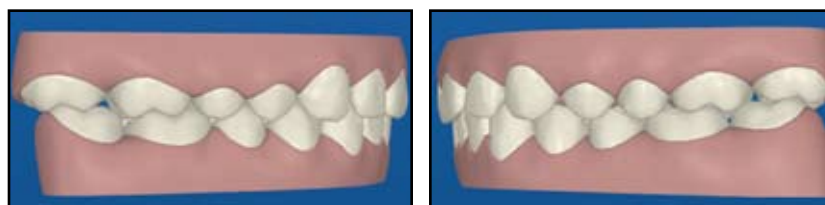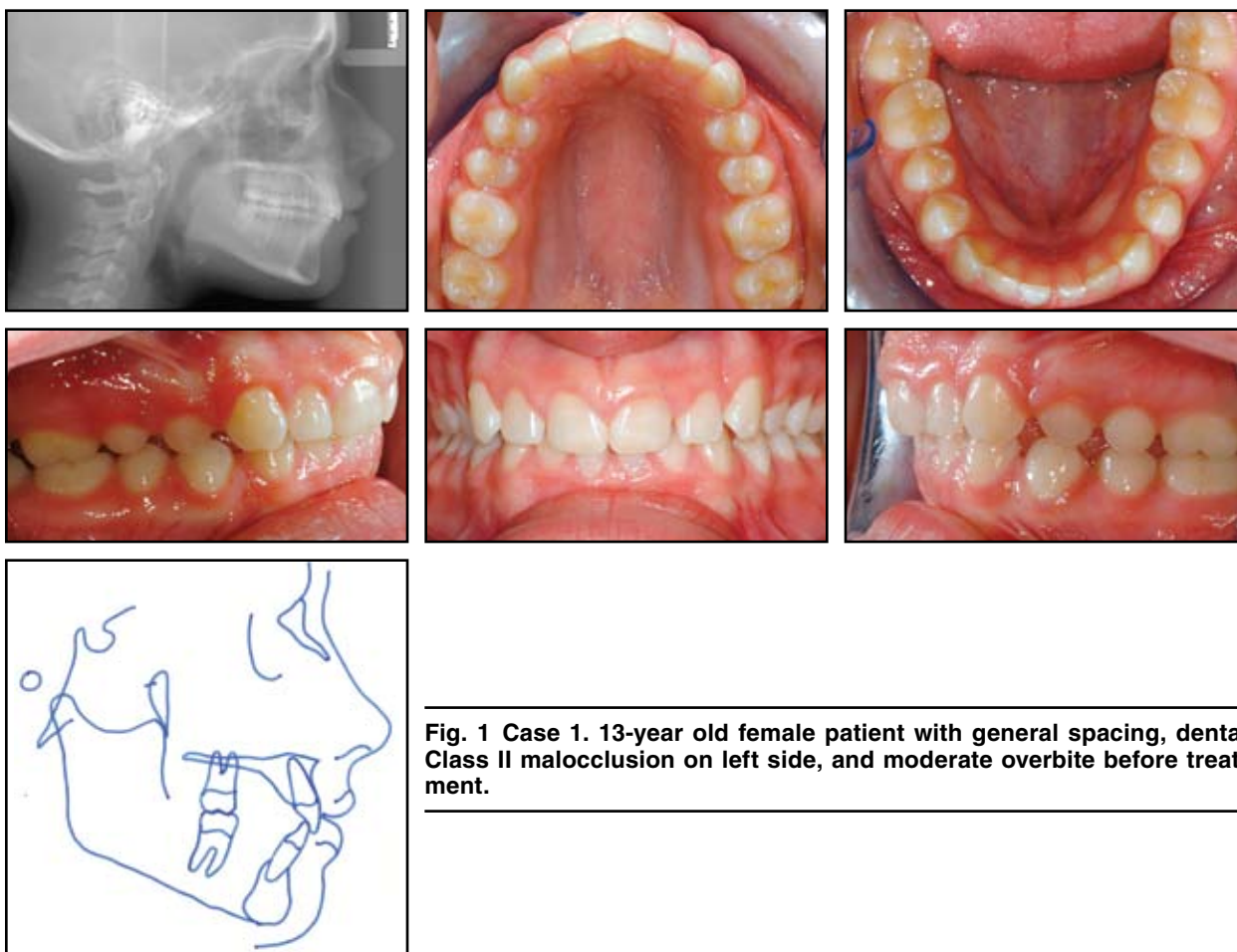


Fig. 2 Case 1. ClinCheck* projection of post-treatment results.

Class I occlusion, and then allow the third molars to erupt into the positions of the extracted second molars.

After extraction of the unerupted lower third molars and the upper second molars, distalization of the upper first molars into the extraction spaces proceeded efficiently (Fig. 6). This patient's treatment began before the development of the current Align Protocol,¹ which would have accelerated the premolar distalization without waiting for molar distalization to be completed.

The case required minor interproximal reduction in both arches and placement of attach-

ments on the upper canines, first premolars and first molars. No midcourse correction or refinement aligners were needed. The patient was cooperative with her aligner wear, completing active treatment in 26 months (Fig. 7A). Since the lower arch was corrected well ahead of the upper, it was held with a clear, vacuum-formed retainer until the upper anterior retraction had been completed; a passive lower lingual 3-3 retainer was then bonded. Small residual interproximal spaces between the upper first and third molars were subsequently closed with a Hawley retainer. The upper third molars took about two years to erupt into the sec-

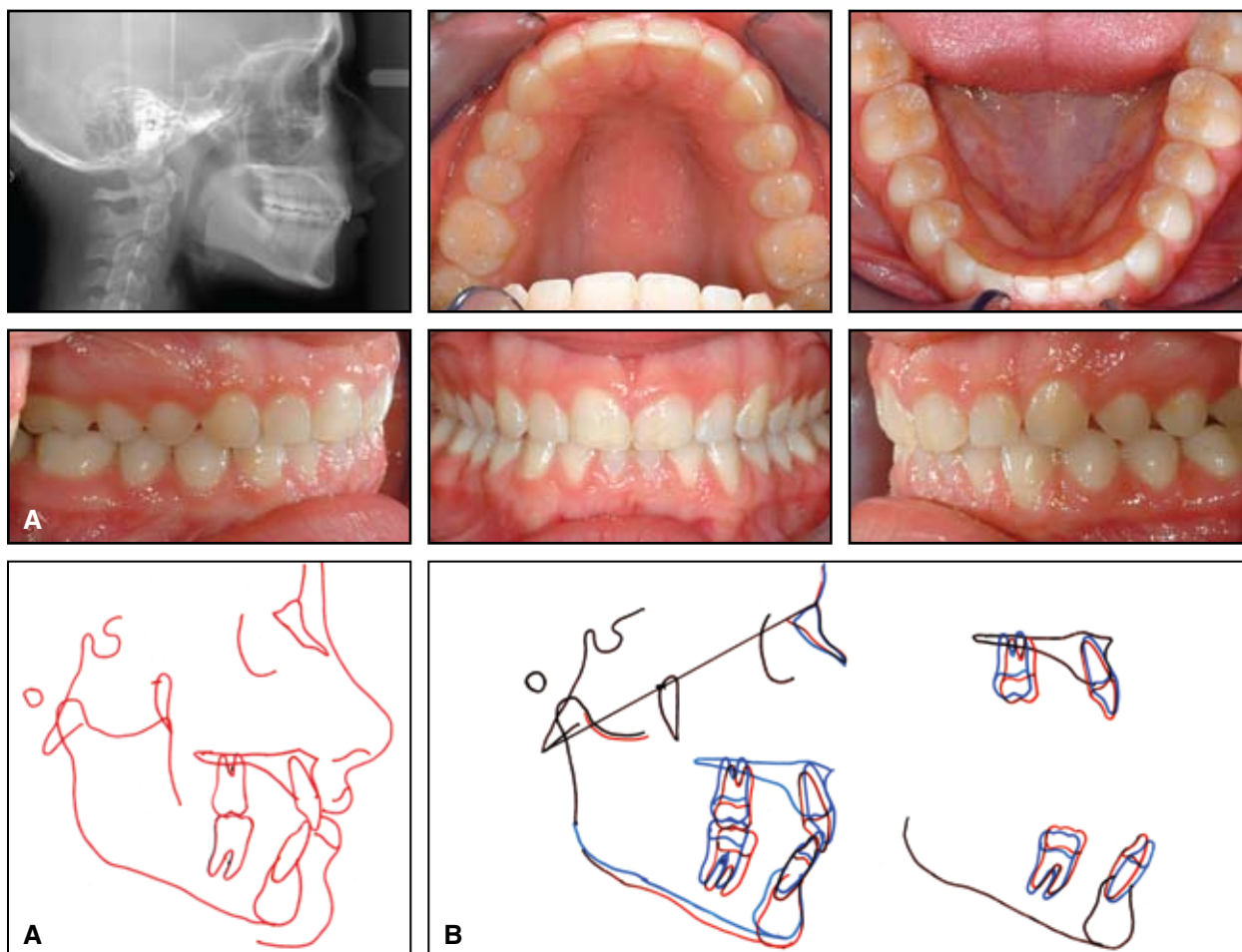


Fig. 3 Case 1. A. Patient after 16 months of treatment. B. Superimposition of pre- and post-treatment cephalometric tracings.

ond molar extraction spaces.

All the objectives were accomplished, and the patient was highly satisfied with her treatment experience. Superimposition of the pre- and post-treatment cephalometric tracings showed forward

mandibular repositioning and growth (Fig. 7B). The upper molars were held back from mesial and occlusal growth, the upper anteriors were retracted, and the lower dentition remained stationary, as the ClinCheck analysis had predicted.

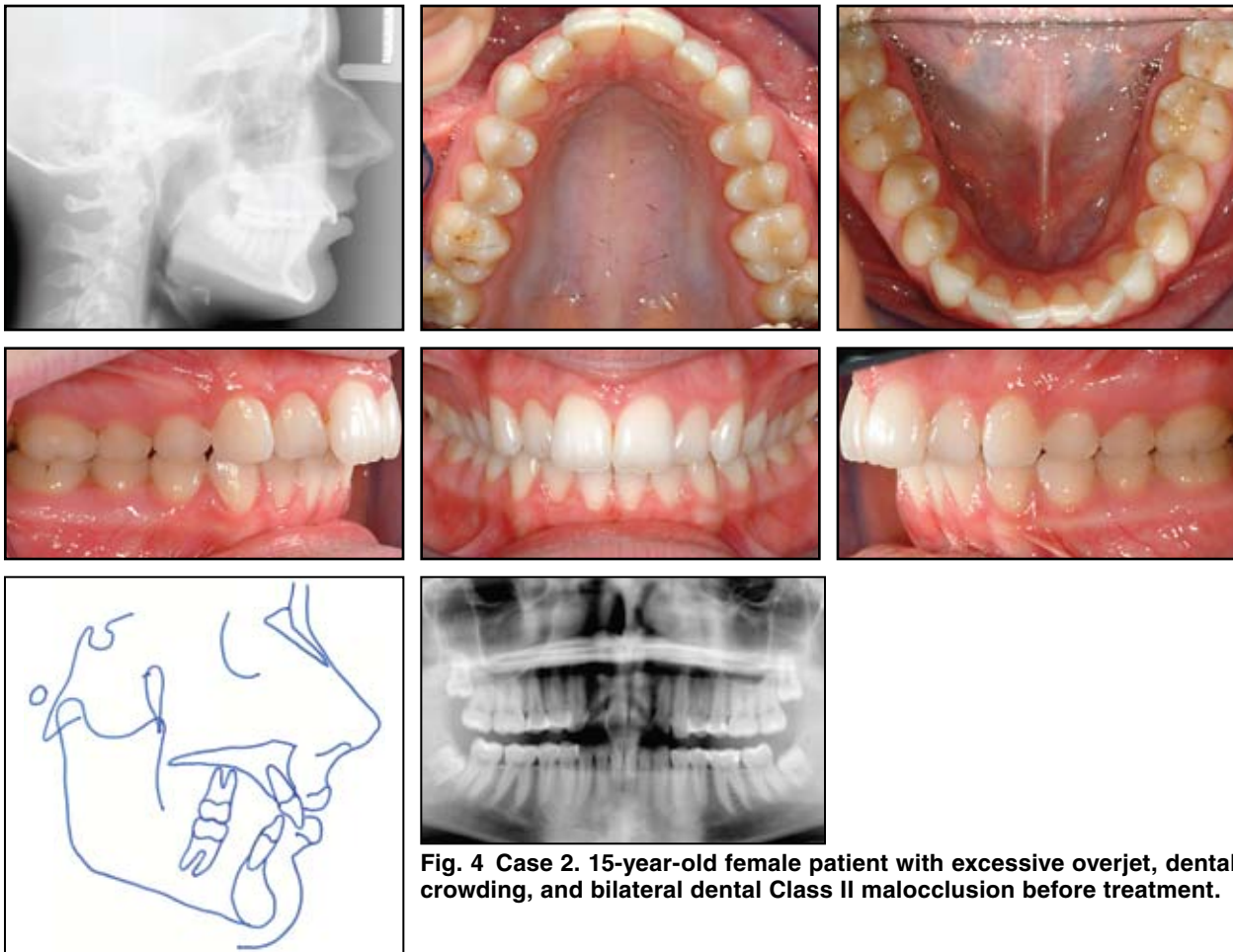


Fig. 4 Case 2. 15-year-old female patient with excessive overjet, dental crowding, and bilateral dental Class II malocclusion before treatment.

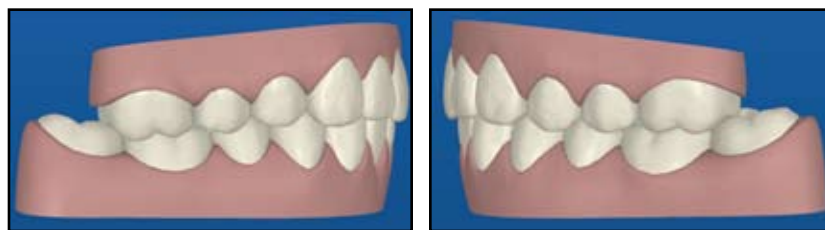


Fig. 5 Case 2. ClinCheck projection of post-treatment results.

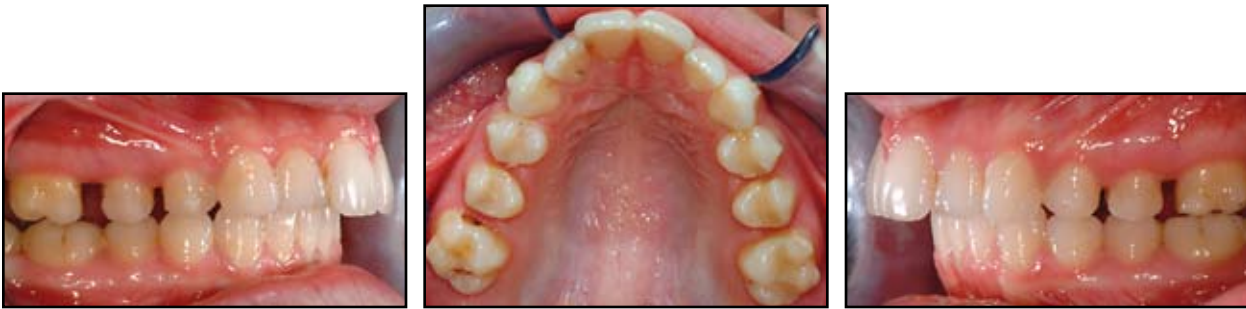

Fig. 6 Case 2. After 10 months of first-molar distalization following second-molar extraction.

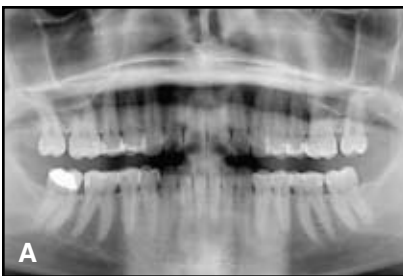
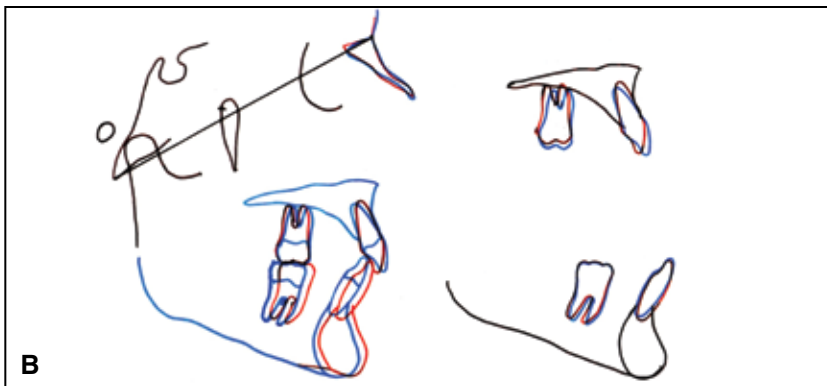
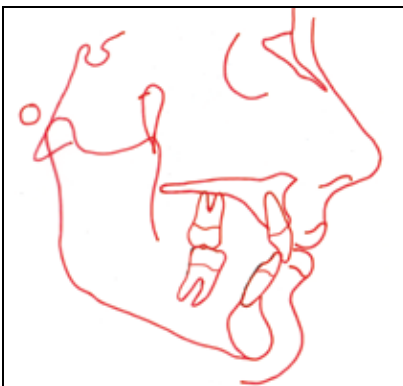
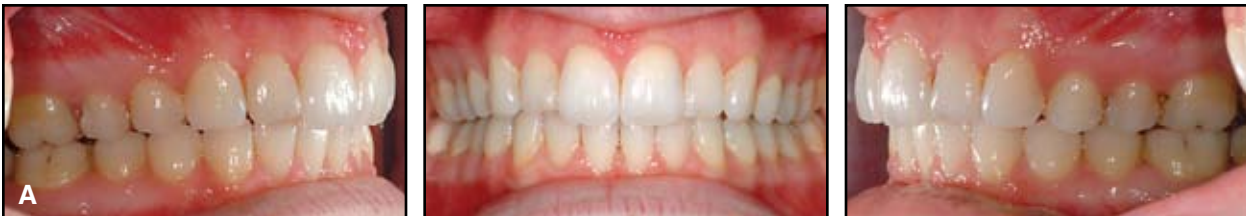
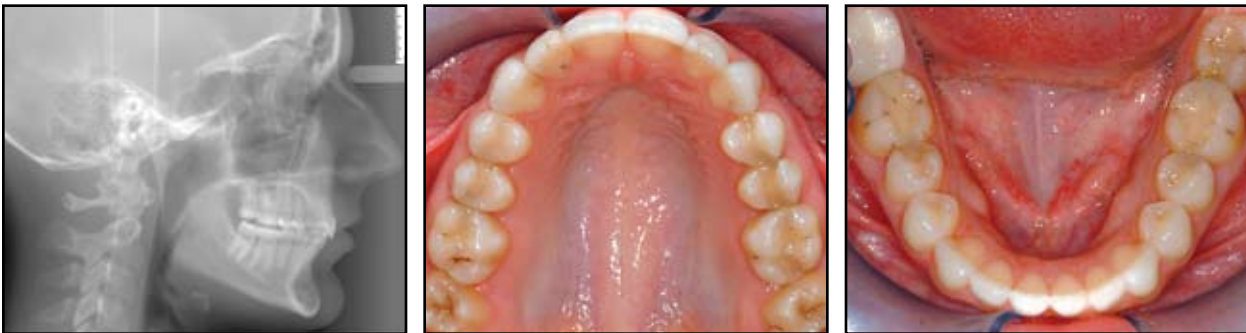Fig. 7 Case 2. A. Patient after 26 months of treatment. B. Superimposition of pre- and post-treatment cephalometric tracings.

Case 3

A 14-year-old female presented with concerns about excessive crowding in both arches (Fig. 8). She exhibited a deep bite and a bilateral Class II dental relationship. Her craniofacial type

was mesognathic, with no skeletal imbalance, and the soft-tissue profile was satisfactory.

The treatment objectives were to correct the patient's deep bite and rotated upper lateral incisors and first molars and to achieve a full Class I

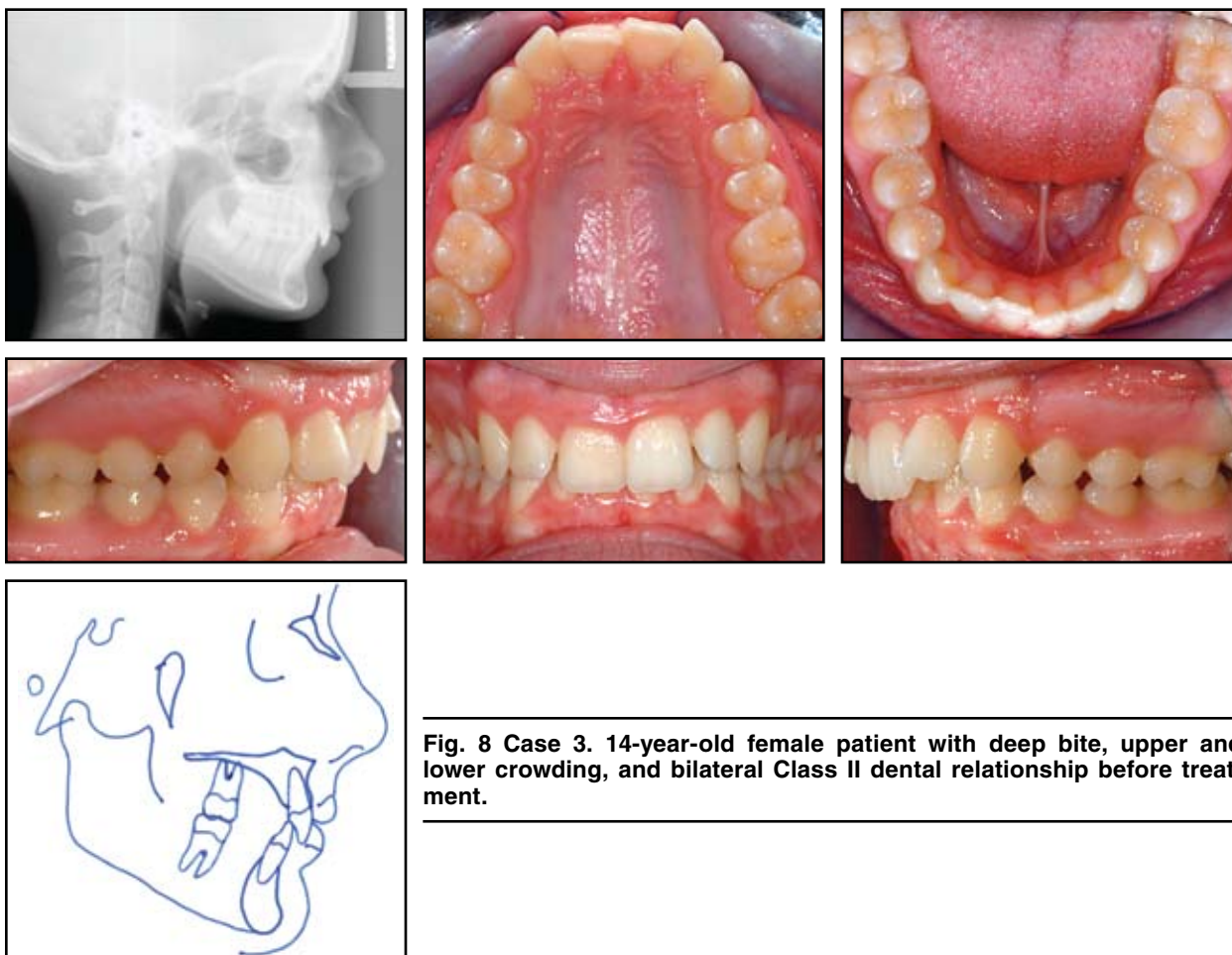


Fig. 8 Case 3. 14-year-old female patient with deep bite, upper and lower crowding, and bilateral Class II dental relationship before treatment.

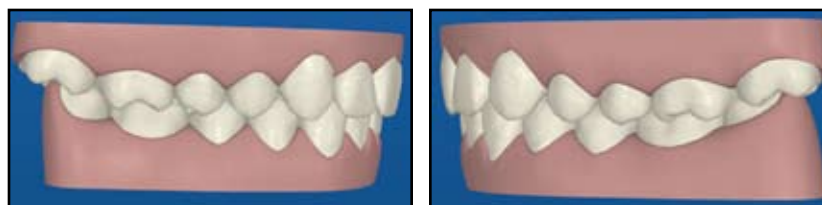


Fig. 9 Case 3. ClinCheck projection of post-treatment results.

occlusion, using 32 upper and 12 lower aligners over 18-24 months. Since the unerupted upper third molars were still high in the tuberosity, this patient was a good candidate for distalization of the upper first and second molars. The ClinCheck projection included intrusion of the upper anterior teeth to help correct the deep bite (Fig. 9). Attachments were placed on the upper central incisors, first and second premolars, and first molars, and on the lower canines and first premolars.

Moderate interproximal reduction was performed on the lower central incisors and the lower left lateral incisor and canine. One lower and four

upper refinement aligners were required to correct the upper lateral incisor rotations.

After 24 months of treatment, a full Class I occlusion had been achieved (Fig. 10A). At this point, a small residual rotation of the upper left lateral incisor remained, and the deep bite had not been adequately corrected. When offered a second set of refinement aligners to remedy these issues, however, the patient declined further treatment. Cephalometric superimpositions demonstrated forward maxillary and mandibular repositioning and growth. The upper molars moved along with mesial and occlusal growth, the upper anterior

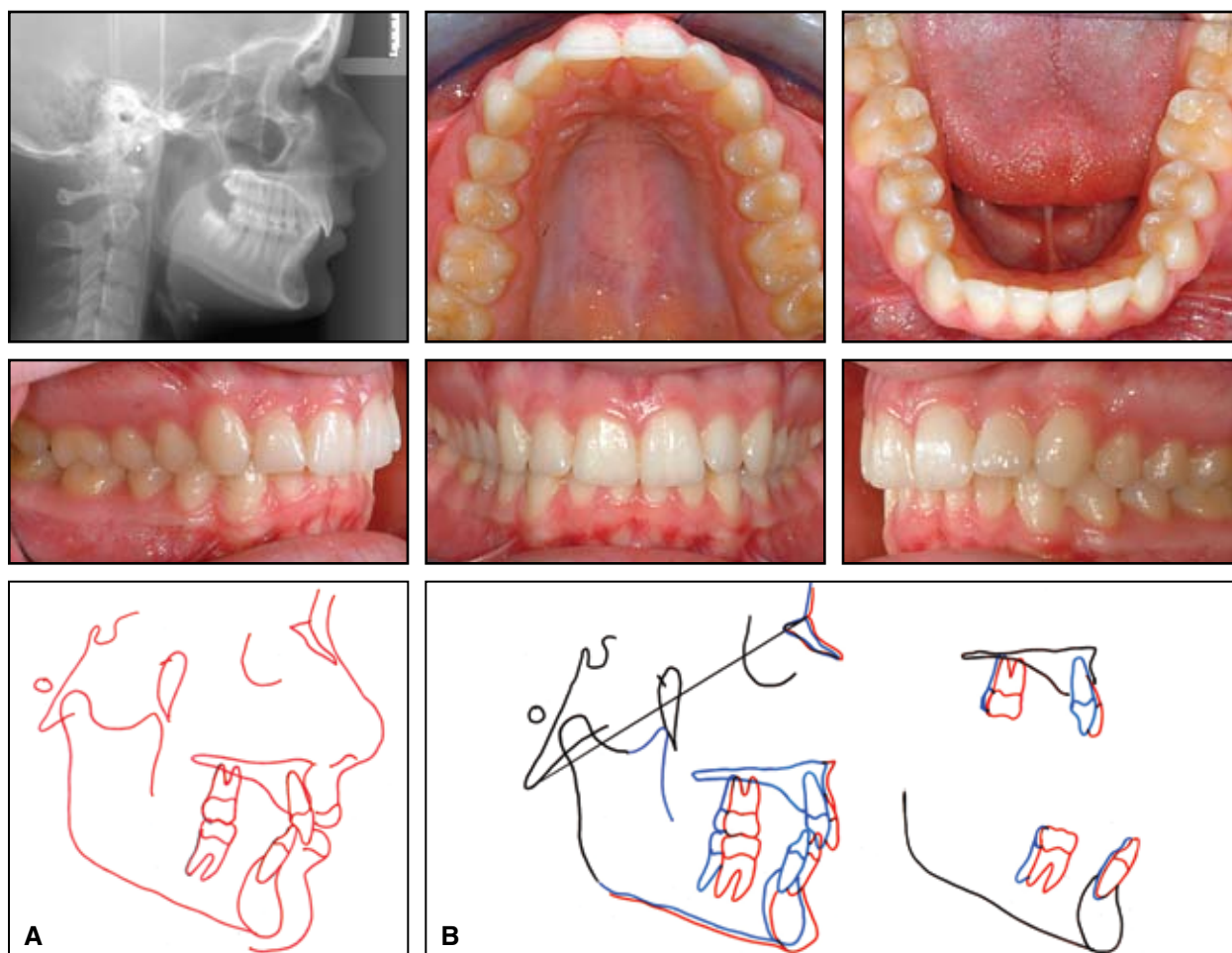


Fig. 10 A. Case 3. Patient after 24 months of treatment. B. Superimposition of pre- and post-treatment cephalometric radiographs.

teeth were advanced, and the lower dentition was moved mesially, as predicted by the ClinCheck (Fig. 10B).

Discussion

The use of elastic traction with aligners for dental Class II correction is a well-documented treatment protocol.^{2,3} Buttons or brackets can be bonded to individual teeth for connection of elastics, but each aligner must then be trimmed to fit around the bonded attachments. The alternative of “notching” the aligners allows elastics to be hooked directly to the plastic,⁴ but this is still a time-intensive procedure. The recently introduced G3 version of Invisalign makes it possible to incorporate these alterations directly into the design process, so that the aligners can be fabricated with the prescribed adjustments.

A lesser-known technique, as shown in Cases 2 and 3, can distalize the maxillary molars with aligners only, avoiding the need for auxiliaries such as elastics, headgear, or mechanical distalizers. To achieve success with this technique, however, it is imperative that the clinician be familiar with the current Align Protocol¹ for attachments, staging, and rates of tooth movement; with the relevant anatomy, particularly the maxillary tuberosity and the pterygoid plates of the sphenoid bone; and with the concept of anchorage unique to the aligner appliance.

Small, rectangular or ellipsoid attachments should be bonded to the buccal surface of any molar being distalized to increase the area for application of the distal pressure built into each aligner. Because the movement of molars, with their large, multiple roots, is difficult with any technique, it is imperative that initiation of this movement be staged early in the aligner sequence and completed as soon as possible. The rate of movement expressed by each individual aligner should be slowed to a minimum.

Before distalizing a maxillary molar, the clinician must consider any limitations posed by anatomical circumstances—for example, the erup-

tion status and location of the third molar. A tooth being distalized by aligners needs an unobstructed path of movement. In addition, the lateral cephalogram must be appraised to determine whether there is enough room in the maxillary tuberosity to accommodate the distalized teeth. The proximity of the anterior border of the pterygoid plates of the sphenoid bone can restrict the size of the maxillary tuberosity and thus the space available for distalized molars.

Newton’s third law of motion, “For every action there is an equal and opposite reaction”, cannot be disregarded when using aligners to move teeth. A distalizing force on the posterior teeth exerts an equal and opposite vector on the anterior teeth. The aligner tray’s flexibility and tight-fitting contours, along with the anchorage provided by groups of anterior teeth, provide effective resistance to the distalizing forces and prevent unwanted displacement of anterior teeth, similar to the effect of a Nance appliance.

Conclusion

The cases presented here clearly demonstrate the effectiveness of Invisalign aligners in correcting dental Class II malocclusions without the use of auxiliaries. Still, I cannot overemphasize how important it is for the clinician to develop a thorough knowledge of the current Align Protocol and to acquire sufficient Invisalign experience before attempting the complex movements required for successful completion of these types of cases.

REFERENCES

1. Sterental, R.: Understanding the latest Invisalign innovations: Improving clinical results for a broader range of patients, *Ask the Expert*, Align Technology, October 2009.
2. Schupp, W.; Haubrich, J.; and Neumann, I.: Class II correction with the Invisalign system, *J. Clin. Orthod.* 44:28-35, 2010.
3. Daher, S.: Predictable treatment of Class II malocclusion exclusively with Invisalign, 2008 Invisalign Summit for Orthodontic Practices, November 2008, Las Vegas, NV.
4. Guarneri, M.; Gracco, A.; Farina, A.; and Schwarze, J.: Attachment of intermaxillary elastics to thermoformed aligners, *J. Clin. Orthod.* 43:34-37, 2009.